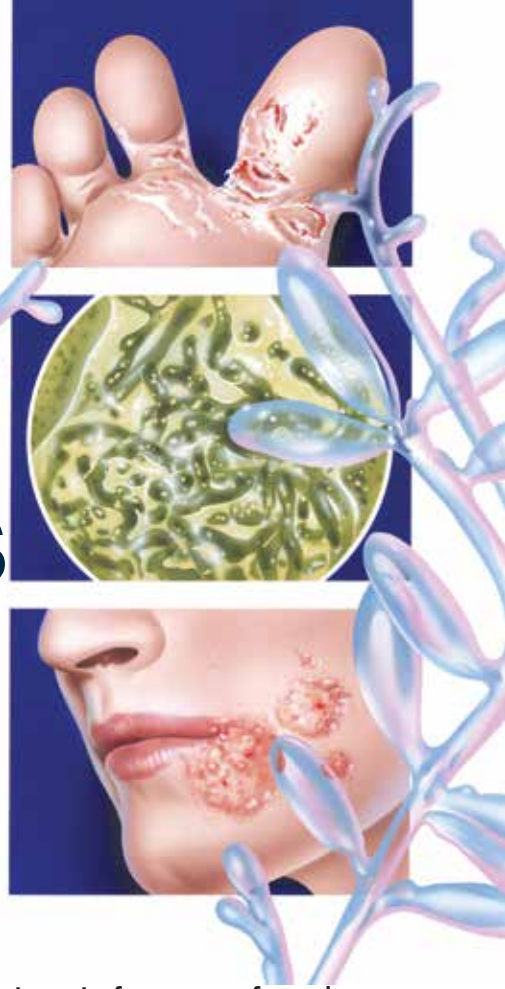


# Therapies for common cutaneous fungal infections



KENG-EE THAI MB BS(Hons), BMedSci(Hons), FACD

## Key points

- Fungal infection should always be in the differential diagnosis of any scaly rash.
- Topical antifungal agents are typically adequate treatment for simple tinea.
- Oral antifungal therapy may be required for extensive disease, fungal folliculitis and tinea involving the face, hair-bearing areas, palms and soles.
- Tinea should be suspected if there is unilateral hand dermatitis and rash on both feet – ‘one hand and two feet’ involvement.
- Oral antifungal treatments can often be pulsed intermittently, reducing the overall dose required.

A practical approach to the diagnosis and treatment of common fungal infections of the skin and hair is provided. Topical antifungal therapies are effective and usually used as first-line therapy, with oral antifungals being saved for recalcitrant infections. Treatment should be for several weeks at least.

**T**inea and yeast infections are among the most common diagnoses found in general practice and dermatology. Although antifungal therapies are effective in these infections, an accurate diagnosis is required to avoid misuse of these or other topical agents. Furthermore, subsequent active prevention is just as important as the initial treatment of the fungal infection.

This article provides a practical approach to antifungal therapy for common fungal infections of the skin and hair. It is not intended to be an in-depth treatise on dermatomycoses, and onychomycosis and cutaneous candidiasis are not covered in detail. The initial section briefly reviews the practical pharmacology of commonly used antifungal agents, in order to guide their use. The defining features of various

dermatomycoses (tinea) and yeast infections and their differential diagnoses and treatments are then discussed (Table).

## ANTIFUNGAL THERAPIES

Topical antifungal preparations are the most commonly prescribed agents for dermatomycoses, with systemic agents being used for complex, widespread tinea or when topical agents fail for tinea or yeast infections. The pharmacology of the systemic agents is discussed first here.

### Systemic antifungal agents

#### Terbinafine

Terbinafine is a highly effective antifungal agent, by virtue of its fungicidal property. It is an allylamine and works by inhibiting squalene epoxidase. It has greater affinity for fungal squalene

Dr Thai is a Consultant Dermatologist and Visiting Medical Officer at the Epicutaneous Patch Testing Clinic and Hair and Nail Clinic, Prince of Wales Hospital, Randwick; a Visiting Medical Officer at the Macquarie University Hospital, Macquarie Park; and in private practice in Gordon, Sydney, NSW.

epoxidase than the human type. Inhibition results in a deficiency of ergosterol (an important fungal cell wall constituent) and the accumulation of squalene, both of which disrupt fungal cell membranes. It is especially effective against infections caused by dermatophytes (*Epidermophyton*, *Microsporum* and *Trichophyton*).

About 80% of an oral dose of terbinafine is absorbed, regardless of food intake, but first-pass metabolism limits bioavailability to 40%. Terbinafine is lipophilic and thus widely distributed, with significant and rapid distribution in skin stratum corneum, sebum, hair and nails.

High concentrations of the medication are reached in the stratum corneum within hours of commencement of therapy. After 12 days of terbinafine 250 mg per day, there is enough drug in the skin to maintain a minimum inhibitory concentration (MIC) for two to three weeks after cessation of treatment. Terbinafine is found in the distal nail after one week of therapy, and after six or more weeks of treatment it is detectable for at least another 30 weeks (indicating the potential for continued action). It is also found in the hair after one week of treatment, and may be detected for up to another 50 days after just two weeks of treatment.

As terbinafine is metabolised in the liver and the metabolites are excreted in the urine, dose adjustment is required in patients with renal failure where the serum creatinine level exceeds 300  $\mu\text{mol/L}$ . With the exception of those with renal insufficiency, dose adjustment is not required in the elderly.

Terbinafine is generally a very safe agent. The most common adverse effects are headache, gastrointestinal symptoms and drug eruptions; hepatic and haematological complications are quite uncommon. Blood counts and liver function tests should be performed if terbinafine is to be used continuously for more than six weeks. One peculiar side effect is a disturbance, or even loss, of taste in some patients, which can be irreversible.

Terbinafine has no serious drug

interactions and there are no contraindications to its use with other drugs. However, because it is an inhibitor of cytochrome P450 2D6, care should be taken when administering it to patients taking tricyclic antidepressants and other drugs metabolised by this isozyme.

#### *Griseofulvin*

Griseofulvin was the first important oral antifungal agent available for the treatment of fungal skin infections. Historically its main use was in the treatment of tinea capitis. Being only fungistatic, it is not as effective as the other agents described here.

Treatment needs to be continuous until mycological and clinical cure when griseofulvin is used to treat dermatophyte infections. This often leads to protracted courses (several weeks to months), especially with onychomycosis, for which up to 18 months of treatment may be required. It is important to note that griseofulvin has no activity against the yeasts *Candida* and *Malassezia* (formerly known as *Pityrosporum*).

Typical doses in children are 10 to 15 mg/kg daily, with recalcitrant cases requiring up to 25 mg/kg daily, and in adults, 500 mg to 1 g daily. The medication is best taken with a fatty meal to increase absorption. For children, the tablets can be crushed and administered with, for example, chocolate, full-cream ice cream or peanut butter. The medication is presented to the skin via sweat, concentrating in the stratum corneum. It is quickly cleared from skin and hair after cessation of therapy.

Although well tolerated, side effects are common with the use of griseofulvin and include headaches, photosensitivity, drug rashes, gastrointestinal disturbance, urinary and menstrual disturbances, liver dysfunction and neurological effects (fatigue, mood changes, dizziness, blurred vision). Changes to spermatogenesis occur, and men taking griseofulvin should not father children for at least six months after ceasing treatment.

The use of antacids and  $\text{H}_2$ -antagonists

may reduce absorption of griseofulvin; they should be taken two hours after the antifungal agent. Griseofulvin can increase the metabolism of warfarin and the contraceptive pill. When co-administered with alcohol, patients should be warned about the disulfiram-like reaction that can occur.

#### *Itraconazole*

Itraconazole, a triazole, is useful in the treatment of onychomycosis and dermatomycoses. It is also useful for infections caused by *Candida*, *Malassezia* and some nondermatophyte moulds. It acts by inhibiting 14 $\alpha$ -demethylase, resulting in inhibition of ergosterol production from lanosterol.

Being a highly lipophilic drug, itraconazole is best taken with a meal. A low pH gastric environment is also useful to aid absorption. In patients who have relative achlorhydria (i.e. those taking  $\text{H}_2$ -antagonists, proton pump inhibitors or antacids) or who are taking the drug on an empty stomach, absorption is aided by the co-administration of a cola soft drink. The drug is often used in a pulsatile manner.

Itraconazole rapidly presents into the stratum corneum and persists for three to four weeks after cessation of therapy. In the nail, a MIC is achieved after only one week of 200 mg itraconazole twice a day. After several one-week-per-month pulses of treatment, the drug can persist for months in the nail plate. Appreciable amounts are present in hair after only one week of therapy, with higher concentrations found with longer pulses. Itraconazole can persist for up to nine months after cessation of therapy.

#### *Fluconazole*

Fluconazole is a commonly used broad-spectrum triazole that, like other azoles, inhibits 14 $\alpha$ -demethylase. However, it is much less lipophilic and much less protein-bound than other azoles. It has very high bioavailability and its absorption is not affected by food.

When used as a once-a-week 150 mg pulse, fluconazole is present in the skin

**TABLE. TREATMENT OPTIONS FOR COMMON CUTANEOUS FUNGAL INFECTIONS**

Fungal infection	First-line therapy	Second-line therapy	General notes
Tinea corporis, Tinea capitis, Tinea cruris, Tinea faciei, Tinea manuum	Topical terbinafine Topical imidazoles	Oral terbinafine 250 mg for 2 to 4 weeks Fluconazole 200 mg weekly for 2 to 4 weeks (off-label use) Itraconazole 200 mg twice daily for 1 week per month for several months Griseofulvin 500 mg daily for several weeks	Keep skin dry Identify and eliminate source
Tinea incognito	Oral agent as above, with topical agent as adjunct		Cease topical corticosteroid use Identify and eliminate source
Tinea pedis – interdigital type	Topical terbinafine or econazole – spray-on lotion Topical miconazole – tincture	Add topical mometasone furoate lotion to reduce inflammation	Dry feet and interdigital spaces thoroughly, e.g. with hair dryer
Tinea pedis – moccasin type	Topical terbinafine – cream Topical imidazoles	Typically needs oral agent Oral terbinafine 200 mg daily for 2 to 4 weeks Fluconazole (off-label use) or itraconazole as above	Add antifungal powders to shoes Wear open shoes whenever possible, go barefoot at home Remove shoes under desk at work
Kerion	Oral terbinafine 250 mg daily until clinically and mycologically cured Antidandruff shampoo daily to reduce shedding of fungal elements Cephalexin 500 mg three times daily to treat secondary bacterial infection	Fluconazole 200 mg weekly until cured Itraconazole 200 mg twice daily for 1 week per month Griseofulvin 500 mg daily until cured Prednisone 0.25 to 0.5 mg/kg daily if significant inflammation or scarring	Treat with oral agent until clinically cured and hairs start regrowing
Seborrhoeic dermatitis	Scalp and body disease: daily antifungal shampoo for scalp and body for 10 days; then twice weekly long-term. Treat top half of body, down to groin; leave shampoo lather on for 10 minutes each time. Change type of shampoo with each new bottle Facial disease: topical imidazoles or topical combination therapy such as hydrocortisone 1% with either miconazole 2% or clotrimazole 1% creams	Fluconazole 200 mg weekly for 4 weeks	Daily scalp shampooing to reduce accumulated scale Always use conditioner to restore moisture to hairs
Pityriasis versicolor	Econazole 1% as a foaming solution over 3 nights or antidandruff shampoo as for seborrhoeic dermatitis, followed by twice weekly antifungal shampoo long-term	Fluconazole 200 mg weekly for 4 weeks (off-label use) Itraconazole 200 mg once daily for 7 to 10 days	Discolouration takes months to even out

after the first dose, and with continuous therapy can persist several days after cessation. It is present in the nail after one dose as well, but after several months of once-weekly therapy, it is still present in the nail after six months.

As the drug is primarily cleared by renal excretion, a dose adjustment is needed when there is renal impairment (creatinine clearance, less than 50 mL/min). There is no need for dose reduction in renally impaired patients receiving a single dose for vaginal candidiasis.

Fluconazole is very well tolerated. Headache, gastrointestinal upset and mild liver function test abnormalities are uncommon. At very high doses, anorexia and hair loss have been reported.

#### *Ketoconazole*

Oral ketoconazole was deregistered and discontinued in Australia and New Zealand in December 2103 because of its risk of hepatotoxicity.

Before its discontinuation, oral ketoconazole was the oldest of the systemic imidazoles available for the treatment of fungal infections but had been largely replaced in clinical practice by terbinafine, griseofulvin, itraconazole and fluconazole. It was, however, considered still useful in the treatment of widespread pityriasis versicolor because of its significant excretion in eccrine sweat, a 10-day course being generally regarded as being reasonably safe.

#### **Topical antifungal agents**

Topical antifungals are the most common agents prescribed for dermatomycoses. In general, dermatophyte infections are better treated with terbinafine, and yeast infections with the imidazoles. Regardless of the treatment used, general measures that keep infected areas dry and in good condition are just as important.

#### *Terbinafine*

Being both fungistatic and fungicidal, terbinafine is likely to be the most effective topical antifungal therapy. As mentioned earlier, it is highly lipophilic and efficiently

absorbs into and binds the stratum corneum, sebum and hair follicles. High MICs are achieved in the skin after a few days of therapy, and its avidity for the keratin layer helps prevent reinfection during treatment.

Creams and spray formulations of terbinafine are available. Creams are effective on the body and can be used with little irritation in the folds. Spray preparations are useful in the interdigital areas, as the sprayed lotion dries on the skin, avoiding maceration. Twice-daily applications are most practical.

Terbinafine is a well-tolerated topical agent and should be considered a first-line therapy for dermatophyte skin infections. It is important to note that it is not effective against *Candida* or *Malassezia* infections.

#### *Imidazoles*

The topical imidazole antifungals are the most commonly prescribed antifungal preparations. This group includes ketoconazole, bifonazole, clotrimazole, econazole and miconazole. They are effective against most dermatophytes and against *Candida* and *Malassezia*. Of interest, miconazole and econazole also show modest antibacterial properties and may be serendipitously efficacious in treating erythrasma, ecthyma and mild impetigo.

Practically, the various topical preparations are equivalent in efficacy. They should be used twice daily for dermatophyte infections, to increase efficacy and to ensure that if forgotten occasionally, patients are still getting therapy every day. Clinicians should become familiar with a few products in different bases, i.e. creams, lotions, tinctures, powders and shampoos, allowing different agents to be used in different situations.

Topical imidazoles are often used to treat tinea pedis. The interdigital spaces are often moist with prolonged use of shoes and socks. Thus, putting a cream preparation here can perpetuate the maceration that occurs with tinea infections. Spray-on lotions are useful in this site, as the product can dry on the skin and not leave a boggy

mess. Tinctures are also useful in the toe webs, as they dry the area applied to by virtue of the alcohol base (they are also useful under the nail plate). Some commercial tinctures, however, can stain the tissues.

Antifungal powders can be dusted into skin folds, helping dry the area. However, a powder used with any cream can result in a gritty paste, which causes irritation. The author finds powders most useful when placed in shoes; they do not treat the tinea pedis per se, but can reduce the rate of re-infection by reducing the fungal load in the shoes and socks.

Antifungal shampoos are useful in the treatment of seborrhoeic dermatitis. The two key clinical pearls of wisdom are to leave the lathered preparation on for up to 10 minutes before rinsing to allow the antifungal agents to work, and to regularly rotate shampoos to reduce the risk of resistance to one active agent. In extensive tinea capitis, antifungal shampoos are used with a systemic agent in order to reduce the spread of fungal spores from the scalp.

A foaming solution of econazole is useful in the initial treatment of pityriasis versicolor or seborrhoeic dermatitis.

A two-part proprietary treatment kit is available for onychomycosis: a urea-containing ointment that is applied to the nail for one to three weeks to soften it, allowing most of it to be scraped away, and bifonazole cream that is then applied daily for four weeks.

Imidazole preparations formulated with hydrocortisone acetate (as are available for clotrimazole and miconazole) have the added benefit of the corticosteroid's mild anti-inflammatory effect. These are useful where an inflammatory rash or itch accompanies the infection, such as with seborrhoeic dermatitis on the face and when there is irritancy and candidal co-infection in tinea of the skin folds.

#### *Amorolfine*

Amorolfine is a broad-spectrum topical antifungal agent that also acts by disrupting fungal cell membranes through inhibition



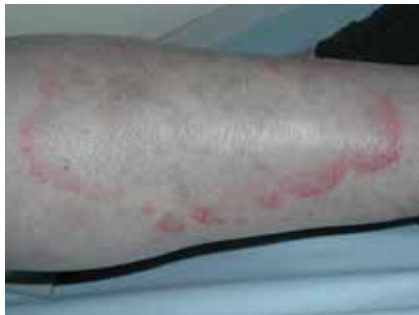

Figure 1. Tinea corporis on a leg. Note the active, advancing border, central clearing and scale. Skin scrapings should be performed from the edges.

of ergosterol synthesis. It is available as an over-the-counter lacquer paint formulation for the treatment of onychomycosis caused by dermatophytes and yeasts. Although early clinical trials showed some benefit, it is relatively expensive, has variable effectiveness and is unlikely to be useful for extensive, deep onychomycosis; systemic agents are best used for these infections.

Patients are required to file down the affected nail and apply the preparation on a once- or twice-weekly basis until the onychomycosis is cured. Most patients give up with this treatment; of those who do use it for more than a year, less than half will achieve clinical cure. The role of amorolfine may well be only for white superficial onychomycosis.

### Role of topical corticosteroids

Traditionally, the use of topical corticosteroids for treating cutaneous infections has been discouraged. When potent topical corticosteroids are used on dermatomycoses, the annular erythema of the rash can be reduced, making it look quite non-specific. Thus the 'ringworm' loses its classic appearance – tinea incognito – and misdiagnosis can result. Furthermore, topical corticosteroids can reduce the body's inflammatory/immune response to the infection and thus facilitate its spread.

The availability of several combination products, however, is testament to the usefulness of corticosteroids in the adjuvant

treatment of infections that have a significant inflammatory component. The key to avoiding misuse of a topical corticosteroid in fungal infections is an accurate diagnosis in the first instance. Tinea should always be considered in any eruption that is scaly or has an annular or serpiginous appearance, and skin scrapings should be taken for fungal microscopy and culture.

Once antifungal therapy has commenced, it is reasonable to occasionally add in a topical corticosteroid, tailoring the potency to the degree of inflammation, to reduce the inflammatory itch and discomfort. Corticosteroids can also help restore the integrity of the skin and improve its barrier function as the fungal infection is being treated. Practical examples include adding a corticosteroid lotion to an imidazole lotion/spray in the treatment of inflammatory interdigital tinea, and using topical or systemic corticosteroids in addition to antifungal therapy in the treatment of highly inflammatory tinea capitis in children to reduce hair loss and scarring.

### COMMON CLINICAL DERMATOMYCOSES

Dermatomycoses are caused by dermatophytes and some yeasts. The three classic sources of dermatophyte infections – or tinea – in humans are animals (zoophilic dermatophytes), the soil (geophilic dermatophytes) and other humans (anthropophilic dermatophytes). These infections of skin, hair and nails can present in a similar fashion, although the zoophilic types tend to be somewhat more inflammatory. It may be important to identify the source of the fungus in order to prevent further reinfection or spread to others; for example, a new guinea pig, cat or other pocket pet may be the source of facial tinea in a young child (through cuddling of the pet), and a child with a kerion may well disseminate the tinea to classmates.

Fungal infections of the skin and hair tend to be treated similarly regardless of the specific fungus causing the infection.

One common classification of tinea is

based upon the body site infected, and this is the classification followed in the discussion below of common dermatophyte infections (tinea infections of the nail – tinea unguium, or onychomycosis – are common but beyond the scope of this article). Two *Malassezia* infections are also discussed. The treatments of these fungal infections are summarised in the Table.

### Body – tinea corporis

Tinea corporis, classically known as 'ringworm', presents as erythematous patches with scales on the trunk, arms or legs (Figure 1). There should be an 'active' border with accentuation of the clinical findings; this is the spreading edge of the patch of tinea. Patches may be quite large and extensive with long-term infections, but the classic features of scale and activity at the border should be present. Multiple patches may be found, and tinea in other body sites should be sought.

**Tinea incognito.** Patches of tinea inadvertently treated with topical corticosteroids will look less impressive, with less erythema and little scale. This disguises the true nature of the dermatophyte reaction, hence the term 'tinea incognito'. Rashes that are spreading or poorly responsive to topical corticosteroids should prompt the consideration of corticosteroid-modified tinea.

**Fungal folliculitis.** Fungal folliculitis can occur in hair-bearing skin, manifesting as follicular pustules in an area of tinea. It can be accentuated by the use of topical corticosteroids.

### Differential diagnoses

The many differential diagnoses for the annular or discoid rash of tinea corporis include the following:

- discoid eczema – the dry and scaly rash is rounded but not often annular (i.e. no central clearing); it can be intensely itchy, whereas tinea corporis may not be
- psoriasis – is typically a thicker plaque than tinea corporis, with thicker silvery scales, and not annular; it should be sought on the extensor

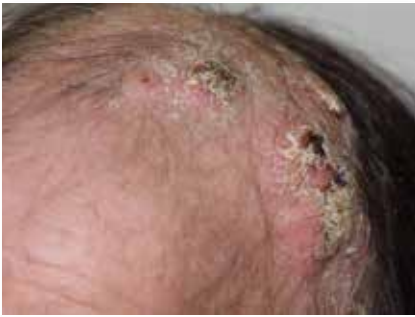

Figure 2. Kerion of the scalp.

- surface of the elbows and knees
- granuloma annulare – is also ring-like, but occurs much more slowly and insidiously; there is never scale, as it is a deeper dermal eruption
- fixed drug eruptions – tend to have a peculiar pigmented, red or purple appearance, and scale is not often a feature; new lesions occur with continued medication use, and older ones reactivate in the same spot
- subacute cutaneous lupus erythematosus – can present as an annular and polycyclic eruption that is scaly and may have the appearance of an active border, thus looking very much like tinea; however, it is found in a photo-distributed area, with worsening after solar exposure. Arthritis, facial rash and other manifestations of cutaneous lupus should be sought
- annular lichen planus – although typically occurring on the genitals, this can inadvertently have an annular appearance on the body. The rash is made up of small purple, raised papules with a characteristic lacy scale (Wickham's striae) on the top of the papules; itch is often a feature
- erythema annulare centrifugum – is one of several rare annular rashes that represent a 'reaction pattern' to a variety of stimuli; in most cases no cause is found. These lesions start as a small patch or papule that evolves slowly to a larger annular patch, with a characteristic rim of scale that has the free edge on the inner side of the ring.

### Treatment

Unless the clinician is absolutely certain of the diagnosis, skin scrapings from the edge of an annular rash should always be taken to diagnose tinea corporis. Microscopy should show fungal elements, and culture will identify the variant of fungus and sensitivities to aid treatment. A skin biopsy can be useful to rule out the more sinister differential diagnoses.

As mentioned previously, identification of the infection source is important to reduce reinfection. Tinea corporis in an individual may be due to autoinoculation from another body site; tinea pedis, tinea cruris and onychomycosis should be sought.

General measures such as fastidious drying of skin folds is important. Treatment with topical terbinafine is generally more effective than with an imidazole. Treatment should occur twice daily for several weeks, until the rash disappears completely. Any other sources in a patient should be treated, and strategies for preventing reinfection may be needed (such as improving personal hygiene, taking more care in public showering facilities or having the family pet treated for fungal skin infections).

Fungal folliculitis, extensive tinea corporis, tinea incognito, kerion or any other atypical fungal infection should be treated additionally with an oral antifungal agent. Treatment should continue until clinical cure is achieved. Oral terbinafine is highly effective (250 mg daily for at least two to four weeks until the rash settles). It is not on the Pharmaceutical Benefits Scheme for this indication, but generics are available that make it a viable option. Fluconazole 150 to 200 mg weekly for up to four weeks is therapeutic and economical (off-label use). Itraconazole 200 mg twice daily for one week per month is an alternative, but the cost in Australia is prohibitive. Oral griseofulvin 500 mg daily is a traditional treatment, but less efficacious than other agents. With any prolonged oral therapy, liver function tests may be appropriate every six weeks or so to exclude hepatotoxicity.

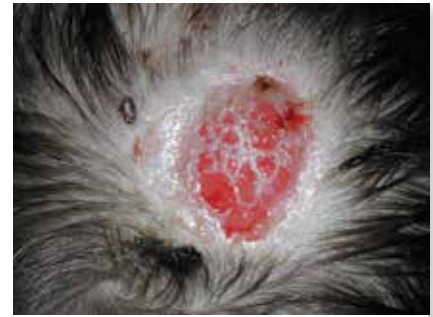

Figure 3. Extensive inflammatory scarring and resultant hair loss around a kerion of the scalp.

### Scalp – tinea capitis

The clinical presentation of tinea capitis can vary greatly. Typically there is a patch of hair loss with easily extractable hairs but different species of dermatophyte will cause differing degrees of scaling and inflammation. The variants are:

- alopecia areata-type – discreet patch of hair loss with dull-grey hairs coated with the fungal spores (ectothrix infection)
- black dot tinea – linear patches with the hair shafts broken at skin level (endothrix infection); there is minimal scale, although a low-grade folliculitis is often seen
- agminate folliculitis (diffuse pustular-type) – a sharply-defined dull red plaque studded with follicular pustules
- kerion – a large, boggy, erosive, pustular, inflammatory mass that resembles an abscess (Figure 2)
- favus – a rare variant that has a characteristic 'cup-shaped' scale at the base of the hair shaft.

Scarring from excessive inflammation can lead to permanent hair loss (Figure 3).

### Differential diagnosis

Although it is important to recognise other scalp disorders that can have scale and hair loss, differentiating tinea capitis is usually straightforward. Alopecia areata has no scale associated, nor does trichotilomania. Seborrhoeic dermatitis should have no hair loss. Psoriasis has thicker, adherent scale, and alopecia is not common. Other scarring

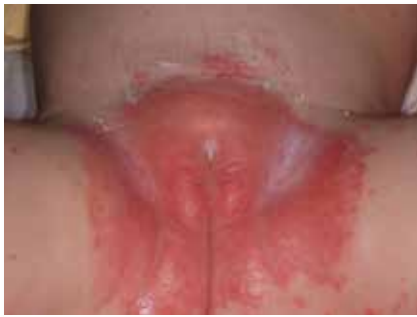

Figure 4. Candidiasis in the inguinal region. Note the satellite lesions away from the main infection.

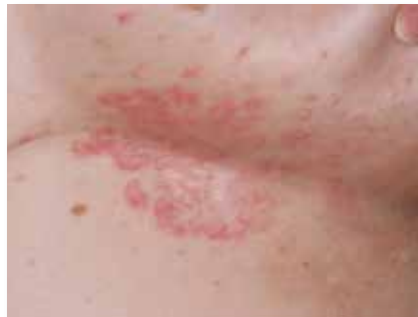

Figure 5. Submammary psoriasis. This can be difficult to differentiate from tinea and seborrhoeic dermatitis.

alopecias such as folliculitis decalvans, lichen planopilaris and dissecting cellulitis of the scalp are chronic conditions, each with a different quality of inflammation.

**Treatment**

Skin scrapings and hair plucks should be sent for fungal microscopy and culture to confirm the diagnosis and help guide therapy.

As for other types of tinea, other body sites of fungal infection should be sought in an attempt to identify a source. Use of an oral antifungal agent is mandatory because of the involvement of hair follicles. Terbinafine is often the first choice, given at 250 mg daily for several weeks until clinical and mycological cure is achieved. The author’s empirical habit is to review treatment after six weeks, including a liver function test and looking for settling of the inflammation and regrowth of hairs; further therapy may be required. In children, the daily dose of terbinafine is adjusted to body weight: for children weighing up to 20 kg, use 62.5 mg (i.e. a quarter of a tablet); for those weighing 20 to 40 kg, use 125 mg (half a tablet); and for those above 40 kg, use the full adult dose (250 mg; one tablet).

Griseofulvin is a traditional agent and is now typically used as a second-line treatment for tinea capitis, at a dose of 500 mg/day for adults and 10 mg/kg/day for children for six weeks or longer. Higher doses may be required in children (15 mg/kg/day) or

recalcitrant cases (up to 1 g).

Should either terbinafine or griseofulvin be contraindicated, the use of fluconazole (off-label use) or itraconazole is reasonable. The doses would be as for tinea corporis but treatment should be continued until clinical and mycological cure is achieved.

The daily use of an antidandruff shampoo is also useful to reduce the continued shedding of spores from the patient’s scalp. Furthermore, it may be important to keep a child away from school for the first two weeks of the infection, reducing the risk of spread to his or her schoolmates.

Although kerion may resemble an abscess, incisional drainage is not useful as there is no cavity, only inflammatory granulation tissue. Often, however, there is a coexistent bacterial infection. If this is the case, an oral antifungal agent and a broad-spectrum antibiotic such as cephalexin should be used. Antifungal therapy is prolonged, typically at least six weeks. Excessive inflammation may lead to scarring alopecia; dermatologists may use oral corticosteroids in some cases to limit this inflammatory scarring.

**Skin folds – tinea cruris**

A typical site for flexural tinea is the inguinal fold. Tinea cruris is easily diagnosed and presents as a flexural erythematous rash with an active border; there may not be a lot of scale, given the occluded nature of the groin, but the rash is often itchy. Although most commonly ascribed to

adult men, tinea cruris can occur in teenagers and women. Once again, there may be tinea at other sites, and the feet and nails should be checked. Scrapings for fungal microscopy and culture confirm the diagnosis.

Note that chronic tinea corporis often involves skin folds and can be rather recalcitrant to therapy.

**Differential diagnosis**

Infectious differential diagnoses for tinea cruris are candidiasis and seborrhoeic dermatitis:

- candidiasis – wet, macerated erythematous folds with whitish discharge may be due to candidiasis, which is characterised by the presence of ‘satellite lesions’, red papules or pustules further away from the main front of the erythematous rash (Figure 4). The submammary fold is a common site for candidiasis. It is important to remember that terbinafine is not effective in the treatment of candidiasis and that the imidazole antifungals work for both candidiasis and dermatophyte infections
- seborrhoeic dermatitis – can present in the flexures (the axillae and pubic areas are common sites), although it more often occurs in the scalp and eyebrows and on the face and chest. The rash is pale pink with friable, loose small scales.

Noninfectious differential diagnoses for tinea cruris are flexural psoriasis and irritant contact dermatitis:

- flexural psoriasis – has no scale, involves the depth of the fold and has a characteristic glazed appearance; the submammary and the inguinal folds are typical sites of involvement (Figure 5)
- irritant contact dermatitis – dermatitis secondary to urine in the folds can be seen in infants as napkin dermatitis and in the neglectful elderly as an ammoniacal dermatitis. This eczematous rash typically spares





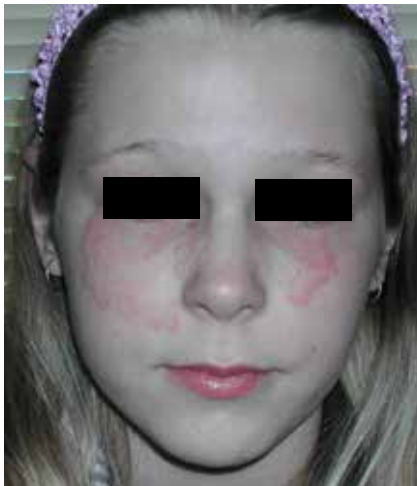

Figure 6. Tinea faciei. The source of the infection was a new kitten.

the depths of the folds, although not always. Co-infection with *Candida* or the incidental presence of a dermatophyte should always be considered.

**Treatment**

Tinea cruris should be treated the same way as tinea corporis, with deliberate drying of the folds being particularly important. A change in underwear style that avoids skin-on-skin contact in the depth of the folds can help aerate the fold and reduce sweating (i.e. a style where there is a layer of fabric on the thigh as well as the genital area; boxer shorts may be too loose and allow the fold to occlude so there is skin against skin).

**Face – tinea faciei, tinea barbae**

Tinea faciei often presents in an annular pattern similar to tinea corporis (Figure 6). However, topical corticosteroids are often prescribed initially, leading to tinea incognito (Figure 7). Solar exposure can worsen the inflammation. As mentioned earlier, pets may be the source of facial tinea, and the possibility that a new pet is the source of fungus should be explored. Although much less commonly recognised than tinea elsewhere, the clinical features of an annular rash with an active border should

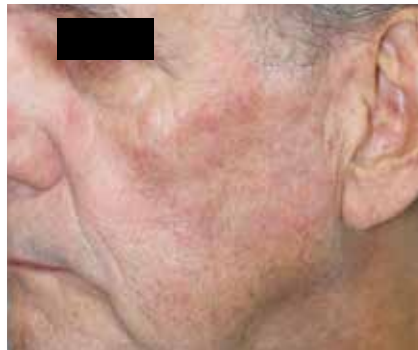

Figure 7. Tinea incognito. Treatment of tinea faciei with topical corticosteroid has obscured its classic features.

help with the diagnosis.

Fungal folliculitis of the beard (tinea barbae) may be quite inflammatory and can present as a kerion; hairs are easily extracted (Figure 8).

**Differential diagnosis**

There are multiple differential diagnoses to be considered with a facial rash. A skin scraping should make the diagnosis of tinea easier. Occasionally a biopsy can be performed, though the clinician needs to consider the legacy of a small scar.

Differential diagnoses include the following:

- seborrhoeic dermatitis and facial psoriasis – as well as being difficult to distinguish from tinea faciei, these two conditions can be difficult to distinguish from each other. Both have an erythematous rash with greasy, loose scales but seborrhoeic dermatitis is typically found on the mid face, over the eyebrows and paranasal sinuses (and as dandruff on the scalp) whereas psoriasis is found on the rest of the body and on the margins of the scalp
- atopic dermatitis and contact dermatitis – atopic dermatitis is common on the face, with the eyelids affected most often in adults. The skin tends to be drier than with tinea faciei, with ill-defined edges to the rash. Contact dermatitis may look similar to atopic eczema; if contact dermatitis is

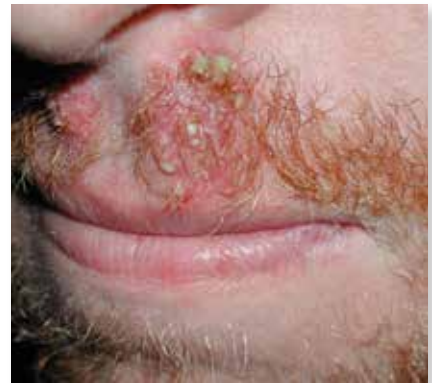

Figure 8. Kerion of the moustache area.

suspected, a history of possible exposure needs to be explored

- rosacea – typically affects the convexities of the mid face (cheeks, nose, chin). Flushing and blushing are common historical features, and the rash is of telangiectasias, background erythema, papules and pustules. There is no active border per se, and rosacea often spares the nasolabial folds. Perioral dermatitis typically occurs around the peri-alip lip, and extends to the skin around the rest of the cutaneous lip and chin, including the nasolabial folds. Papules and pustules accompany the rash. It is associated in many cases with the use of potent topical corticosteroids on the face.
- cutaneous lupus erythematosus – if the rash is photosensitive, lupus should be suspected as it can be quite inflammatory, scaly, scarring and annular. Rash should be sought in other parts of the skin, especially the photoexposed areas, and systemic illness also. A biopsy is mandatory if the patient does not respond to antifungal therapy or if there is systemic illness.

**Treatment**

Therapy is as for tinea corporis; a systemic antifungal is likely to be required for extensive disease, folliculitis and beard kerion.

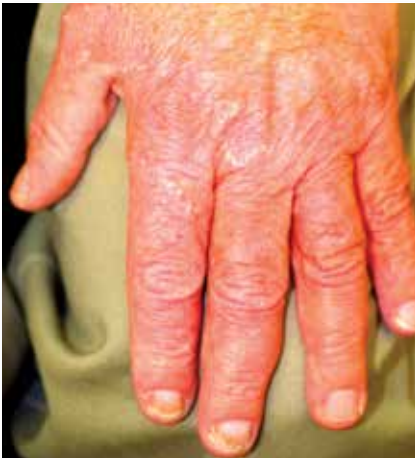

Figure 9. Tinea manuum. Note the scaly, serpiginous superior border just above the metacarpophalangeal joints. Diagnosis is made difficult due to prior topical corticosteroid use.

### Hands – tinea manuum

Tinea of the hands can be difficult to diagnose and is often confused with pompholyx, hand dermatitis, psoriasis and keratolysis exfoliativa. A scaly rash that has an active border should be easily diagnosed as tinea (Figure 9). More often, the presentation is a dry, slightly scaly and peeling erythema of the palmar surface that can be confused with dermatitis. It can also be quite inflammatory, with blisters at the edge, like pompholyx. The rash can affect both the palmar and dorsal surface in continuity with each other. A classic description is that only one hand is involved; the above-mentioned differential diagnoses are often symmetrical.

Other areas of co-infection are possible, and the feet should always be checked as often there is ‘one hand, two feet’ involved with tinea. Onychomycosis can be seen on the fingernails.

#### Treatment

Skin scrapings, fungal microscopy and culture is key to a diagnosis. Topical antifungal agents can be used for small areas. However, given that tinea manuum can be extensive and commonly coexist with other areas of dermatophyte infection, an oral

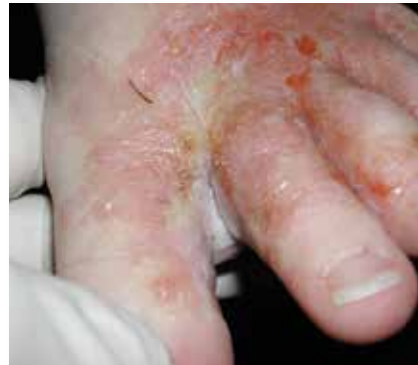

Figure 10. Interdigital tinea pedis. Note the white, boggy macerated skin in the depth of the fold, and the associated inflammatory tinea pedis on the adjacent skin.

agent may be appropriate (see tinea corporis). Once again, treatment is until clinical cure, which can take several weeks.

### Feet – tinea pedis

The feet are an exceedingly common site for dermatophyte infections. Spots of ringworm on the dorsum of the feet are easy to diagnose, but there are several variants that clinicians should recognise:

- interdigital tinea (‘athlete’s foot’) – often occurs in the setting of a wet, macerated webspace, which often has broken, boggy, white skin (Figure 10). This should be seen as an infected irritant intertrigo, where there is both an inflammatory irritant dermatitis as well as the dermatophyte infection. The ringworm component of interdigital tinea may spread to the adjacent dorsum of the foot
- moccasin tinea – describes an erythematous, scaly fungal infestation of the plantar surface of the feet, as if the patient was wearing a pair of ‘fungal moccasins’ (Figure 11). Moccasin tinea is common, and often missed as many older patients have dry scaly feet. An active margin at the sides of the feet, where the erythema and scale appear to stop, should be looked for. It may coexist with interdigital tinea. Skin scrapings

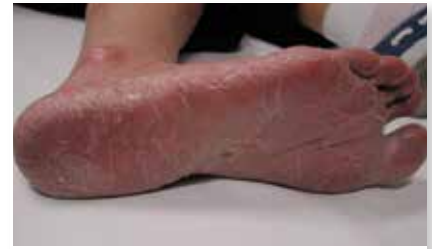

Figure 11. Moccasin tinea pedis. Note the dry scaly fissured infected skin involving the entire sole.

- should be at the edge of the erythema for the greatest yield of hyphae
- inflammatory tinea – highly inflammatory tinea pedis can have vesicles, pustules, erosion and maceration.

#### Differential diagnosis

Differential diagnoses may include bacterial cellulitis, pustular psoriasis and secondarily infected pompholyx. Once again, fungal scrapings for microscopy and culture are useful, but also bacterial swabs to rule out a secondary or co-infection.

In patients with recurrent cellulitis of the legs, it is important to look for and treat tinea pedis. The chronic dermatophyte infection creates broken skin, which is the portal of entry for the bacteria responsible for cellulitis.

#### Treatment

General measures are important to keep the feet as dry as possible. These measures include:

- fastidious drying of the feet and the toe webs after showering – using a hair dryer on a low heat setting can help
- wearing open shoes when possible, to air the feet – if appropriate, desk-bound office workers should remove their shoes when seated to reduce sweating
- regular changes of socks, and laundering at above 60°C to decontaminate them of fungus
- use of antifungal powders in shoes – to help prevent reinfection in the future. With interdigital tinea, therapeutic

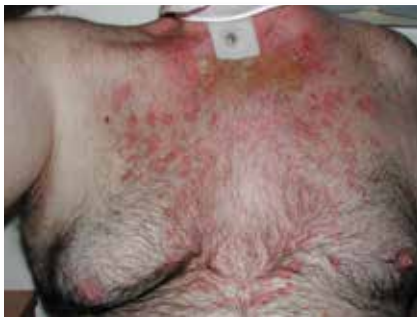

Figure 12. Seborrhoeic dermatitis.

lotions/sprays (e.g. terbinafine spray-on lotion, econazole spray-on lotion or miconazole tincture) should be used as they dry on the skin, whereas cream-based products may encourage more maceration and wetness. If there is excessive inflammation, a topical antifungal can be used in conjunction with a topical corticosteroid lotion, such as mometasone furoate 0.1% drops.

Moccasin tinea and tinea with inflammatory changes can be recalcitrant to topical therapy. Should regular use of terbinafine or an imidazole cream fail, then a systemic antifungal agent should be considered.

### Seborrhoeic dermatitis

Seborrhoeic dermatitis is probably due to an inflammatory response to *Malassezia*. This yeast is a commensal organism on human skin but appears to overgrow in some individuals, leading to an inflammatory reaction.

Seborrhoeic dermatitis presents as a pale pink, ill-defined erythematous rash characterised by loose, flaky scale. Dandruff is seborrhoeic dermatitis on the scalp. The mid face, along the eyebrows, nasolabial folds, and cheeks and beard areas are classically affected. The rash may also be present on the central chest, upper back and in the axillae (Figure 12). Seborrhoeic dermatitis is more common in people who are psychologically stressed, fatigued or in poor general health. HIV infection and other immunodeficiencies are a common association, as are Parkinson's disease, stroke and other neurological diseases.

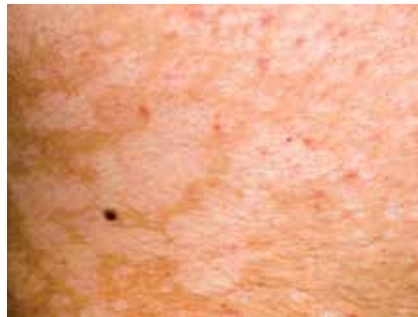

Figure 13. Pityriasis versicolor.

### Differential diagnosis

Psoriasis is the most common differential diagnosis for seborrhoeic dermatitis. Psoriasis, however, has a more chronic course, more intense erythema and a thicker layer of scales. Rash should be looked for on more pathognomonic sites, such as elbows, knees and affected nails. Sometimes it is not possible to differentiate seborrhoeic dermatitis and psoriasis, and the term seborpsoriasis is used.

### Treatment

As the putative cause of this rash is the overgrowth of a commensal organism, treatment is aimed at reducing the skin's yeast load as well as targeting the inflammation.

Facial dermatitis will usually respond to a mild topical corticosteroid/imidazole combination such as hydrocortisone 1%/miconazole 2% cream or hydrocortisone 1%/clotrimazole 1% cream used two to three times daily. Alternatively, ketoconazole 2% cream can be used alone. For more severe inflammation, a mid-potency corticosteroid can also be used, such as desonide 0.05% lotion.

To treat scalp and skin disease as well as reduce the overall yeast load, an antidandruff shampoo is used. Ciclopirox olamine solution has the greatest *in vitro* fungicidal activity, but in practice all antifungal shampoos are equally effective. Patients are advised to wet the scalp and entire skin, and then turn the shower off. The shampoo is used to lather up the scalp hair and as a bodywash to cover the top half of the body, including the face, beard, chest, back, axillae and pubic region.

The treatment rationale is that these areas are where the reservoir of yeast is greatest. Patients should wait for about 10 minutes before rinsing off the shampoo, to allow it time to work. Initial treatment with the shampoo is every day for seven to 10 days to eliminate the yeast. Subsequently, a long-term, twice-weekly, all-over body shampoo regimen limits further fungal overgrowth. Patients should buy a different shampoo (with a different active ingredient) each time, thus preventing the development of antifungal resistance. Any flare of disease should trigger a change in shampoo and another seven to 10-day course of therapy.

Recalcitrant cases can be treated with a short course of oral antifungal agent. Various regimens are available but a simple one involves fluconazole 200 mg once a week for four weeks. The above antidandruff regimen should then be used twice weekly as well.

### Pityriasis versicolor

Pityriasis versicolor is another yeast infection caused by *Malassezia*. It manifests as a salmon-pink spotty, scaly rash on fair skin, and as a paler or white spotty, scaly rash on darker or tanned skin (Figure 13). It is distributed mainly over the back, shoulders, trunk and upper limbs. The infection is most prevalent in the warmer months as the hot, humid, sweaty conditions favour fungal proliferation.

### Differential diagnosis

Pityriasis versicolor may be confused with guttate psoriasis. However, the rash of pityriasis versicolor is macular and the scales are powdery and fine, and that of guttate psoriasis consists of small plaques with thicker scales.

### Treatment

Topical antifungals are effective for pityriasis versicolor, but need to be used over a large area. Econazole is available as a 1% foaming solution specifically for this purpose. This is distributed on wet skin after an evening shower and left on overnight; the top half of the body is treated, including the scalp. Thereafter, a twice-weekly

---

antidandruff shampoo regimen is instituted to reduce the rate of relapse (as for seborrhoeic dermatitis, see above).

Alternatively, recalcitrant cases can be treated with fluconazole (off-label use) or itraconazole.

The characteristic scaling of pityriasis versicolor is a good indication of continued activity, as it disappears with effective fungal clearance. The pink spots disappear over a few weeks, but repigmentation may take months. Patients are advised that should they subject themselves to a suntan within the next few months, the previously affected spots can look very obviously pale. When the next summer does come, patients can use the twice-weekly antidandruff shampoo regimen to reduce the risk of the yeast repopulating their skin.

## CONCLUSION

The key to the effective use of antifungal agents is an initial accurate diagnosis of the fungal infection. The classic finding of the active border and fine scale is pathognomonic of tinea, and dermatophyte infection should always be in the differential diagnosis when dealing with red, scaly rashes.

Topical antifungal preparations are usually adequate treatment for simple tinea but systemic antifungal treatment should be considered with complex, widespread tinea or when topical agents fail. A relatively dry skin is an important general treatment measure. MT

## FURTHER READING

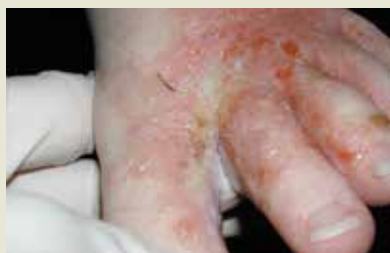Mycology Online. University of Adelaide. <http://mycology.adelaide.edu.au/Mycoses/Cutaneous/Dermatophytosis> (accessed May 2014).

UpToDate. Dermatophyte infections. <http://uptodate.com/contents/dermatophyte-tinea-infections> (accessed May 2014).

DermnetNZ. <http://dermnetnz.org/fungal/tinea.html> (accessed May 2014).

COMPETING INTERESTS: None.

## Online CPD Journal Program



**Cream-based antifungal products are best for interdigital tinea pedis. True or false?**

Review your knowledge of this topic and earn CPD points by taking part in **MedicineToday's** Online CPD Journal Program.

Log in to

[www.medicinetoday.com.au/cpd](http://www.medicinetoday.com.au/cpd)